# UPDATE ON DISEASES OF THE SINUSES AND GUTTURAL POUCHES

David E. Freeman, MVB, PhD, Diplomate ACVS
University of Florida, Gainesville, FL USA

Diseases of the Sinuses and Guttural Pouches are always challenging because of diagnostic limitations and complicated routes of access. This presentation will address current trends in managing these diseases and especially what we have learned from improved diagnostic techniques and treatments. Fitting the correct treatment to each case is rarely easy. Much of the discussion on guttural pouch empyema will cover strangles because of the close relationship between them and the role of the guttural pouch in creating a carrier state.

## Guttural Pouch Empyema

Equine strangles is a purulent lymphadenitis of the upper respiratory tract caused by the Lancefield Group C bacterium *Streptococcus equi* subspecies *equi*. The organism is highly hostadapted. It is a highly contagious disease that can occur at any age, but is more common in young horses. The disease is usually sporadic in older animals. Morbidity is estimated between 30 and 80% (may be 100% in naïve populations of young animals). Mortality is reported between 0 and 10%.

Although the disease involves the upper airways and associated lymph nodes, dissemination to other locations may be hematogenous or via lymphatic vessels to cause abscesses in lymph nodes and other organs of the thorax and abdomen (or even the central nervous system). This is a form of the disease commonly referred to as “bastard strangles”. Nasal shedding of *S. equi equi* usually begins after a latent period of 2 to 3 days and persists for 2-3 weeks after the acute phase in most animals. The incubation period (exposure to clinical signs) is 3 - 14 days, which is the basis for a minimum 14-day quarantine period for new arrivals to a property (ideally 3-4 week quarantine).

After an outbreak, approximately 10% of recovering horses do not clear all infected material from guttural pouches or sinus tracts, and live bacteria can persist in chondroids or on mucosal surfaces in a biofilm for the horse’s life. The guttural pouches are the primary sites of carriage for more than 80% of horses, with the paranasal sinuses accounting for most of the remainder. These chronic carriers are important sources of contagion for other susceptible horses.

Regional lymph nodes, such as submandibular and retropharyngeal nodes enlarge and become firm and painful 2-4 days after onset of fever. The enlarged retropharyngeal lymph nodes can cause respiratory obstruction, but usually are not always externally evident. In most cases affected lymph nodes rupture and drain 7-14 days after the onset of clinical signs and retropharyngeal nodes rupture into guttural pouches to produce a profuse mucopurulent nasal discharge.

Culture of *S. equi* subsp*. equi* from an abscess aspirate, nasal washes or swabs, or guttural pouch flush will confirm the diagnosis. Culture of a nasal wash is more sensitive in detection of *S. equi* subsp*. equi* than a nasal swab, because a greater surface area of mucosa is sampled. Culture of a guttural pouch flush is more sensitive to identify chronic asymptomatic carriers than culture of a nasopharyngeal swab/wash. New triplex qPCR techniques for rapid detection (2 h versus 48 h for culture) of *S. equi* subsp*. equi* DNA in nasal swabs or washes are considered approximately 10 times more sensitive than culture. PCR does not distinguish between live and dead bacteria. PCR testing is commercially available (e.g., Equine Diagnostic Solutions (http://www.equinediagnosticsolutions.com), UC Davis (direct or via Antech and IDEXX), and should be regarded as the gold standard diagnostic test for *S. equi* subsp*. equi*. Detection of

antibodies against SeM-protein does not distinguish between active infection and vaccination and lacks the specificity to be used as a screening test for carrier horses.

**Treatment**

Most cases of strangles are benign, and horses with few systemic signs may not need any treatment other than nursing care. Approximately 98% of horses recover completely within weeks. The key principle of treatment is drainage with strict isolation. Penicillin remains the drug of choice for activity against the strangles organism and to date no resistance has been documented. It can be used in exposed animals with fever but without lymph node abscessation, or in animals that are at risk of asphyxiation or that have “bastard” strangles.

Rifampin can be added in difficult cases or in horses at risk of asphyxiation. Guttural pouch empyema is treated using local flushes through indwelling catheters or repeated endoscopy. Acetlycysteine (20%) into the pouches may aid in resolution of the empyema. A compounded penicillin gel, made from sodium (not potassium) penicillin G and gelatin, can be placed into the affected pouches. Chondroids must be removed, either medically, using a memory-helical polyp retrieval basket, or surgically. To prepare the penicillin gel (Waller), add 2 gm of gelatin to 40 mL of sterile water, heat or microwave to dissolve gelatin, then allow to cool to 45-50 degrees. Add 10 mL of sterile water to 10,000,000 units of Na penicillin G and then mix with gelatin to a final volume of 50 mL. Place in syringes and leave overnight at 4 degrees C to set.

## Complications of Strangles Infections

Complications have been reported in 19 to 42% of strangles cases. Mortality associated with complication to infection may approach 40%. Enlarged retropharyngeal lymph nodes may compress the pharynx, larynx, or trachea resulting in upper respiratory tract obstruction. This may occur even in the absence of overt external swelling. Retropharyngeal lymph nodes may rupture into the guttural pouches resulting in empyema. This complication is common and may result in chronic shedding of *S. equi* subsp*. equi* by affected horses.

Although metastatic abscesses (bastard strangles) can occur anywhere in the body, the most common sites include lung, mesentery, liver, spleen, kidneys and brain. Horses with intra-abdominal abscesses frequently present with chronic weight loss and/or colic. Abdominal abscesses may be palpable on rectal examination.

## Standing Surgical Removal of Inspissated Pus and Chondroids

Many cases of guttural pouch empyema are caused by Streptococcus equi subspecies equi, and can develop inspissated exudate and chondroids. Surgery in such cases should preferably be done as a standing procedure in an isolation facility, so the horse does not move through other parts of the hospital and contaminate surgery suites and anesthetic equipment with a highly contagious organism. Standing surgery also avoids the expense and risks of general anesthesia. A modified Whitehouse approach is used after sedation with detomidine HCl (0.01 mg/kg IV) and butorphanol tartrate (0.03 mg/kg IV) and infiltration with ~30 ml of 2% mepivacaine HCl.

If the guttural pouch is not distended, an assistant can insert a Chambers catheter through the nasopharyngeal ostium into the medial compartment, where the surgeon can help the assistant push it through the mucosal lining at this point. Once the catheter has penetrated, the tip of a hemostatic forceps can be placed in the open end of the catheter tip to guide the forceps into the guttural pouch where it can then be used to expand the opening.

## Arterial Occlusion for Guttural Pouch Mycosis

Methods for occluding the equine carotid arterial system include balloon catheters, microcoils, and nitinol plugs. The transarterial coil embolization (TACE) technique uses angiography to image the affected vessels and identify any unusual branches and sites of bleeding, and then places an embolization coil in the selected portion of the affected artery. Ultrasound (US) guided transarterial coil placement can direct accurate occlusion of carotid branches on the cardiac side of the guttural pouch and identify unusual branching. A combination of US and fluoroscopy can improve catheter guidance and reduce radiation exposure.

Transarterial occlusion with nitinol plugs is the method of choice in the author's hospital (Fig. 1). A nitinol vascular plug is a nickel-titanium wire mesh that expands into a dumb-bell configuration (Fig.1) when delivered to the target segment of artery to be occluded. The procedure is performed under fluoroscopic guidance using an approach and equipment similar to that used for coil embolization. The nitinol plug has the advantage that only a single plug is required at each site whereas at least two transarterial coils are typically used at each site to stop blood flow. The nitinol plug can also be retracted into the delivery cable if placement is unsatisfactory, and migration or dislodgement from the target vessel is unlikely because the expanded plug is held securely by radial tension from the arterial wall. There is little difference in cost between the two methods and both require specialized equipment and expertise.

## Ceratohyoidectomy

The ceratohyoid bone can be surgically removed in horses with temporohyoid osteoarthropathy (THO) to decrease forces on the ankylosed temporohyoid joint and thereby reduce recurrent fractures that exacerbate nerve compression. The ceratohyoid–basihyoid synovial joint is identified and disarticulated with cartilage scissors. The freed end of the ceratohyoid bone is grasped and the ceratohyoid bone dissected from its attachments to the ceratohyoideus, the hyoideus transversus, and the genioglossus muscles. The hypoglossal nerve, lingual branches of the mandibular and glossopharyngeal nerves, and the lingual artery are lateral to the ceratohyoid bone and must be avoided. The ceratohyoid bone can be bluntly separated from its soft tissue attachments with a narrow osteotome or periosteal elevator. The cartilaginous articulation between the ceratohyoid bone and the stylohyoid bone is cut by cartilage scissors or continued elevation with the osteotome, taking care to avoid tension on the stylohyoid bone and temporohyoid joint. The standing procedure has not been described to date in clinically affected horses. The results can vary but some reports indicate recovery in 80% of treated horses with return to use. Treatment with analgesics and oral antimicrobial drugs can be considered if surgery is not an option.

## Nasopharyngeal Obstruction caused by Head Flexion

A recently described form of nasopharyngeal obstruction in adult horses has been attributed to impaired egress of air from one or both guttural pouches during poll flexion, possibly caused by an anatomic or functional defect in the salpingopharyngeal fold. The affected horses might have a form of guttural pouch tympany that is not manifested in the typical presentation in the foal. These horses have a history of respiratory noise and unwillingness to perform in a sport that requires head flexion. A standing laser fenestration of the median septum appears to be effective treatment and can improve performance.

## Ethmoid Hematoma

Ethmoid hematoma is a non-neoplastic, progressive and locally destructive growth in the paranasal sinuses that resembles a tumor in appearance and development. The largest hematomas arise from the ethmoidal labyrinth and smaller, less common lesions originate from the floor and walls of the maxillary sinuses. As an ethmoid hematoma expands, the surface of its

capsule ulcerates, and this causes epistaxis. The expanding hematoma also causes pressure necrosis of surrounding bone and spreads into the frontal sinus, the sphenopalatine sinus, nasal passages, and nasopharynx. An expanding hematoma rarely causes facial distortion, except possibly in foals. It is most commonly seen in horses older than 6 years but most often at 10 to 12 years of age, but has been described in a foal. The disease seems to be less common in Standardbreds than in other breeds and bilateral disease is more common in females. Mild, persistent, spontaneous intermittent and unilateral epistaxis is the most common clinical sign. The hematoma can be seen on radiographs as a smooth-walled, well-circumscribed density that contrasts well with air in the sinus cavity. However, CT is a far superior imaging modality and can identify sites and bilateral disease, so surgery is better guided.

A large frontonasal bone flap is the preferred approach. Horse temperament permitting, this should be a standing procedure with local anesthesia and sedation, to improve access and to reduce hemorrhage, the need for packing and hospitalization. Usually a large opening from the sinus cavity into the nasal passage is created by surgical removal of the hematoma. The recurrence rate after surgical removal of ethmoid hematomas has been estimated at 0% to 44.4% and long term remission of clinical signs was reported as 33% in one study. A recurrence rate of 43% has been reported for bilateral lesions compared with 8% in unilateral lesions in one study. Recurrence may be recognized within the first 6 to 12 months after surgery and repeat endoscopic examination is recommended every 6 months. Improved methods of treatment, especially with improved access through large bone flaps, can facilitate removal of the entire lesion and reduce recurrence. Recurrence should be documented by endoscopy and not clinical signs, because remission of clinical signs does not rule out recurrence.

## Wounds and Fractures

Blunt injuries to the frontal sinus and nasal bones caused by kicks from other horses or collisions with fixed objects cause open or closed wounds to the sinuses. Many can go unnoticed because the fracture fragments are forced into the sinus cavity and the overlying skin detaches from the bone to maintain a normal facial contour. As healing progresses, the hematoma and fracture callous produce a firm, subcutaneous swelling along the fracture line and the depressed bone forms a facial concavity. Epistaxis and subcutaneous emphysema are common clinical signs of sinus trauma and less common signs are dyspnea and epiphora.

The fracture fragments can be exposed through a large curvilinear skin flap. Blood clots are removed and the sinus cavity is flushed liberally with saline solution. To facilitate elevation of the fracture fragments, holes can be drilled in adjacent bone and instruments can be passed through these to pry up depressed fragments. If the fragments wedge firmly together in their normal position and form a stable union, it may be unnecessary to wire them, but large fragments should be wired to parent bone. All small fragments without periosteal attachments should be removed.41 The head should be bandaged so as to cover the wound, if possible, and the horse should recover form general anesthesia either with assistance or wearing a padded headguard. Healing after repair of acute wounds is usually excellent and cosmetically acceptable. In horses with long-standing, healed depression fractures, fluorocarbon polymer and carbon fiber can be used to restore facial contour, or the healed fracture fragments can be cut with a saw and elevated into position. However, a better cosmetic appearance can be obtained by primary open reduction shortly after injury rather than facial reconstruction later. If severe fractures are not treated, complications such as sinusitis, sequestra formation, facial deformity, abnormal bone growth in young horses, and nasal obstruction can be expected.

If a sinus fistula forms to the outside after the sinus wound has healed, a mesh implant and sliding flaps can be used to cover the defects. Tissue expanders can produce sufficient skin to cover the

defect, but skin alone is insufficient. Muscle flaps can be used instead of mesh implants if available close to the defect.

**Role of the Sphenopalatine Sinus in Sinus-related Diseases**

Many sinus diseases in horses are well advanced before they produce the outward signs that lead to a diagnosis. Because of this, these diseases can progress into the deeper recesses of the sinus cavities where they become inaccessible by standard surgical approaches. In such locations, removal of the entire the lesion becomes impossible and recurrence is likely.

There is strong recent evidence that the lesions that pose the most difficulty in treatment and have the highest rate of recurrence are those that invade the sphenopalatine sinuses (SPS). These sinuses are located at the base of the skull, positioned between the brain and ethmoid labyrinth dorsally and the pharynx ventrally. Various critical nerves pass around the outside of these sinuses (cranial nerves II-VI) so that any disease that destroys the wall of the SPS can also damage these nerves. Despite many improvements in access to the major sinuses in the horse's head, an approach to the SPS has not been developed.

A translaryngeal approach to the SPS has been developed in the horse to allow safe access to this important sinus cavity, a clear endosocopic view to its interior, and unrestricted access for long-handled instruments to remove lesions from within, without insult to vital nervous structures within the sinus. The surgical approach is composed of two parts, the first of which is to use a diode laser in a standing transnasal endoscopic approach to remove the pharyngeal mucosa over the bony floor of the sinus along the roof of the nasopharynx, 72 hours before sinusotomy to reduce intraoperative hemorrhage during sinusotomy. Additional laser debridement of the region is repeated as needed before the final sinusotomy to ensure complete mucosal ablation.

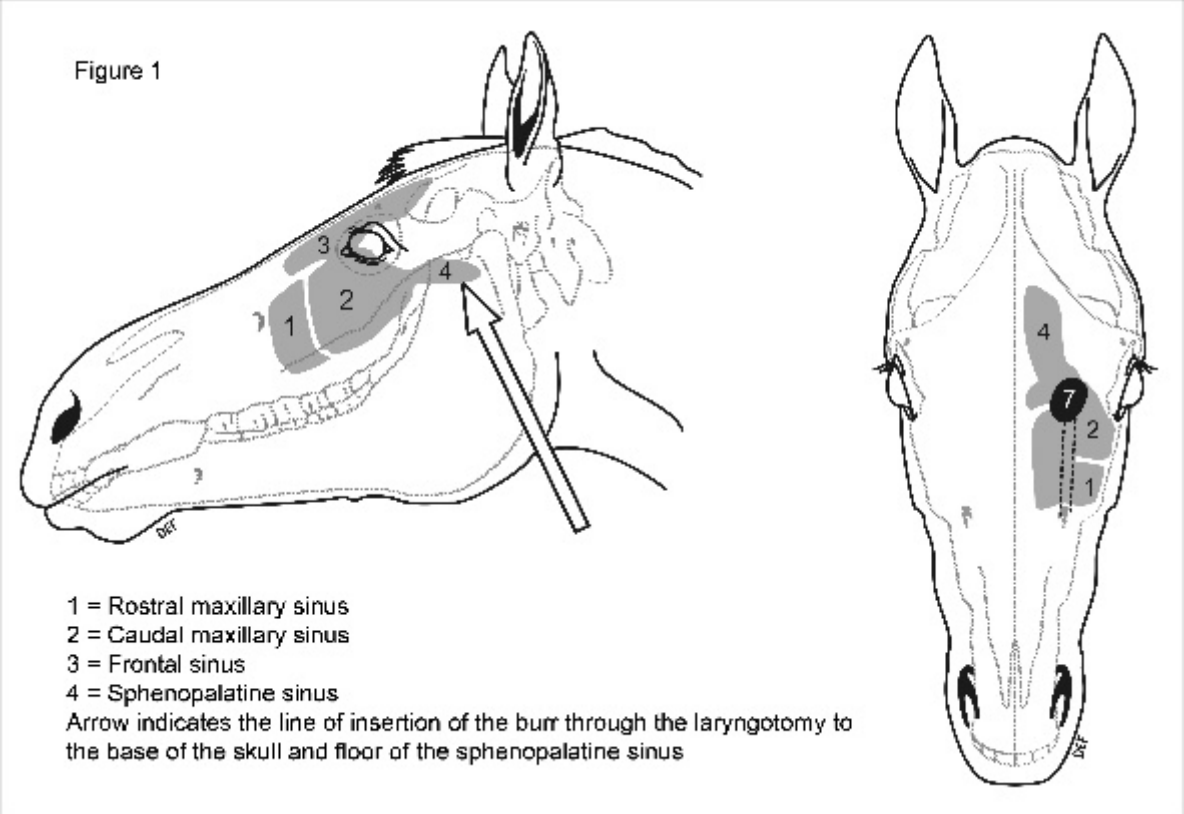

The second part of the surgical approach is performed 72 hours after laser removal of mucosa. With horses were placed under general anesthesia, a routine laryngotomy is performed. A special long shanked burr is passed rostrally through the laryngotomy to the site of denuded mucosa to remove the bone from the floor of the sinus along the roof of the nasopharynx. Transnasal endoscopy is used to facilitate appropriate positioning of the burr and to monitor debridement. With this newfound access to the SPS, we may effectively treat and prevent recurrence of some of the most devastating sinus lesions encountered in horses.

Boyle AG, Timoney JF, Newton JR, Hines MT, Waller AS, Buchanan BR. *Streptococcus equi* Infections in Horses: Guidelines for Treatment, Control, and Prevention of Strangles-Revised Consensus Statement. J Vet Intern Med. 2018;32:633-647.

Waller AS. New perspectives for the diagnosis, control, treatment, and prevention of strangles in horses. Vet Clin North Am Equine Pract. 2014;30:591-607.